

Melanoma Wide Local Excision

Key Simulated Steps and Operative Principles

1. Wide local excision of melanoma with appropriate margin
2. Aesthetic closure of the resulting defect

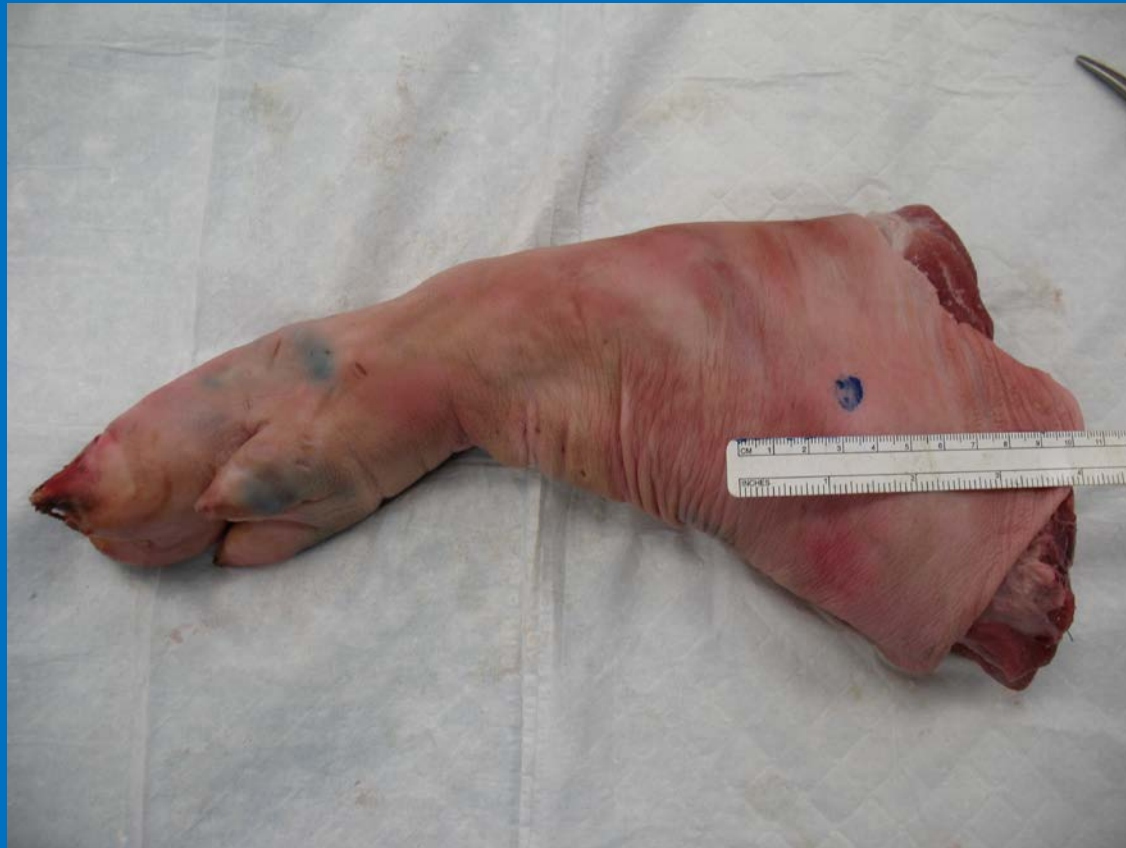Goals and Objectives

1. Determine appropriate surgical margins for wide local excision of melanoma
2. Make surgical incision with tension to avoid skiving
3. Explain when to use cut vs coag when using electrocautery
4. Provide tension and counter tension to allow resecting the skin lesion without charring
5. Demonstrate aesthetic skin closure using vertical mattress sutures

Required Materials

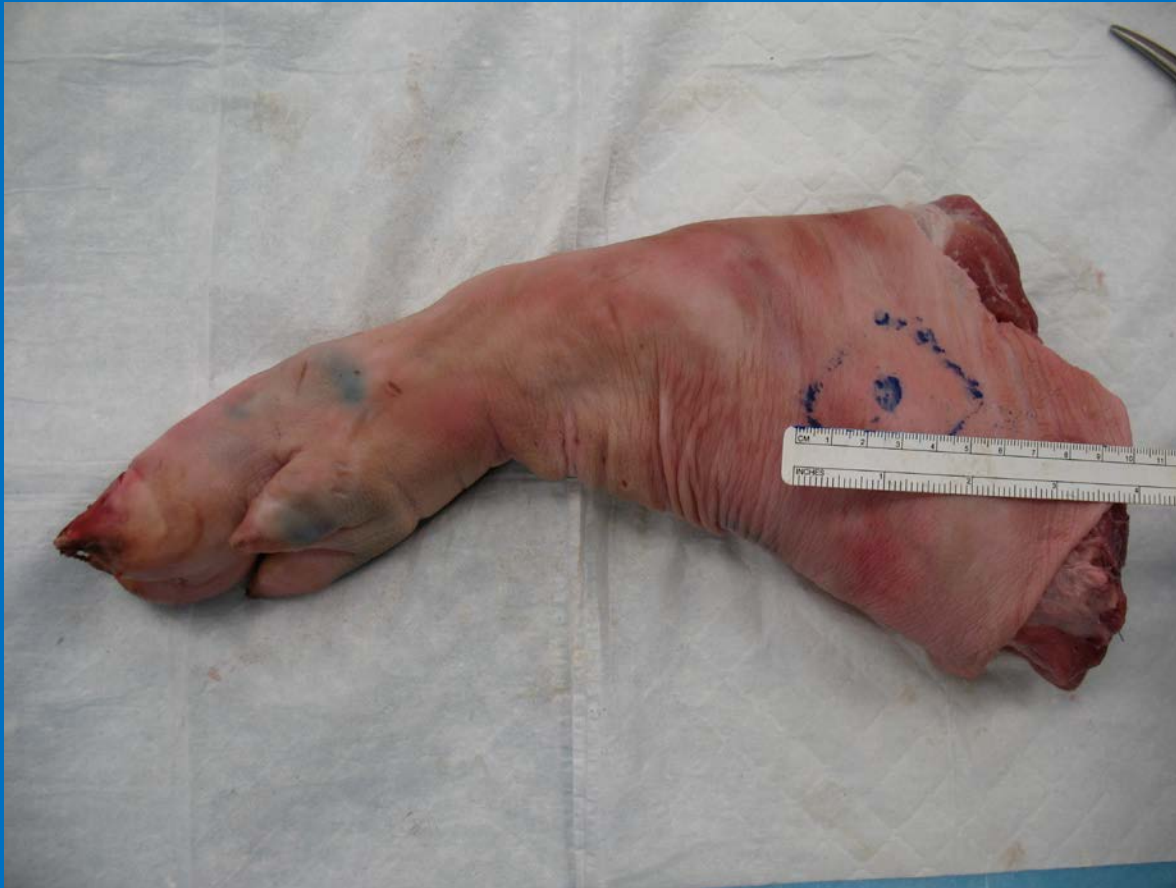1. Pig feet
2. Scalpel with #15 blade
3. Electrocautery
4. Adison forceps
5. 3-0 Nylon sutures
6. 3-0 Vicryl (polyglycolic acid suture)
7. Marking pen
8. Ruler

Setup Step



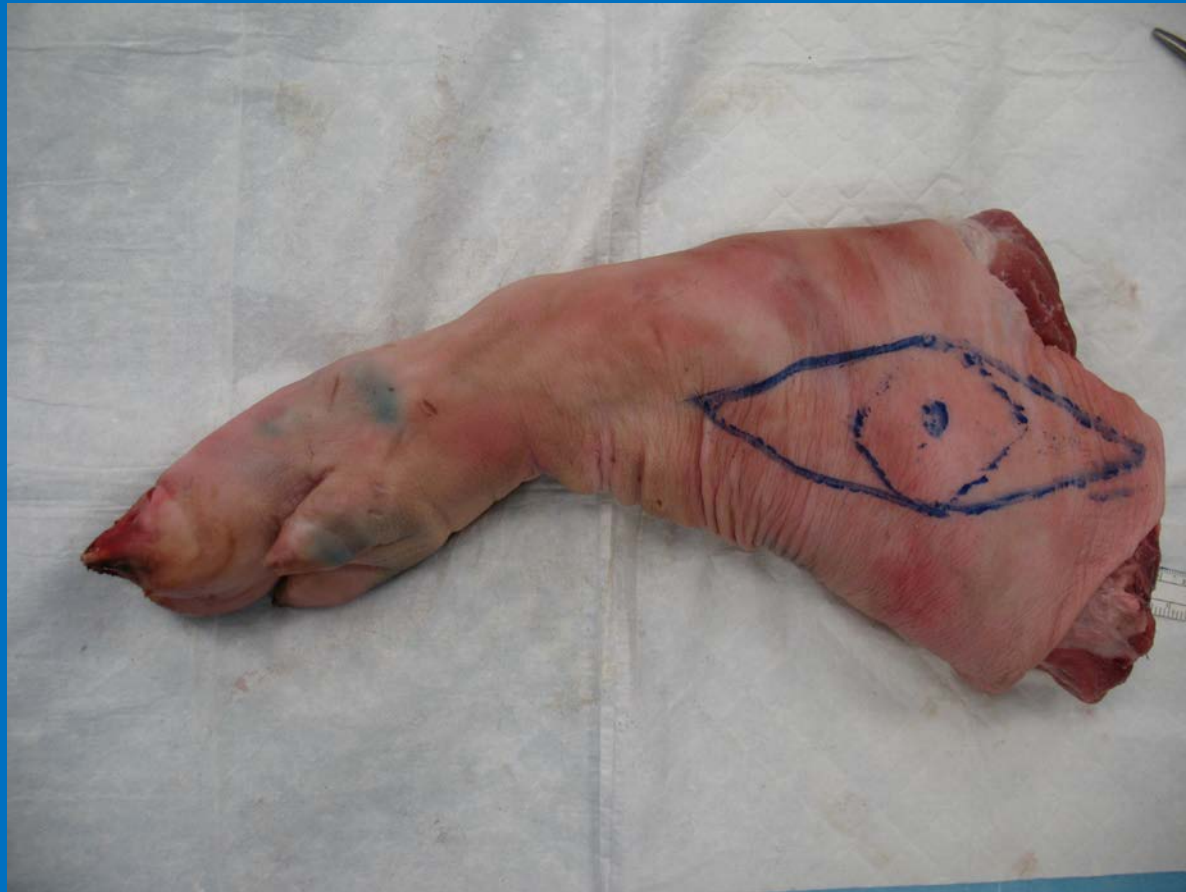Use a marking pen and draw a solid circle with a diameter of 1 cm to simulate melanoma

Procedure Step 1



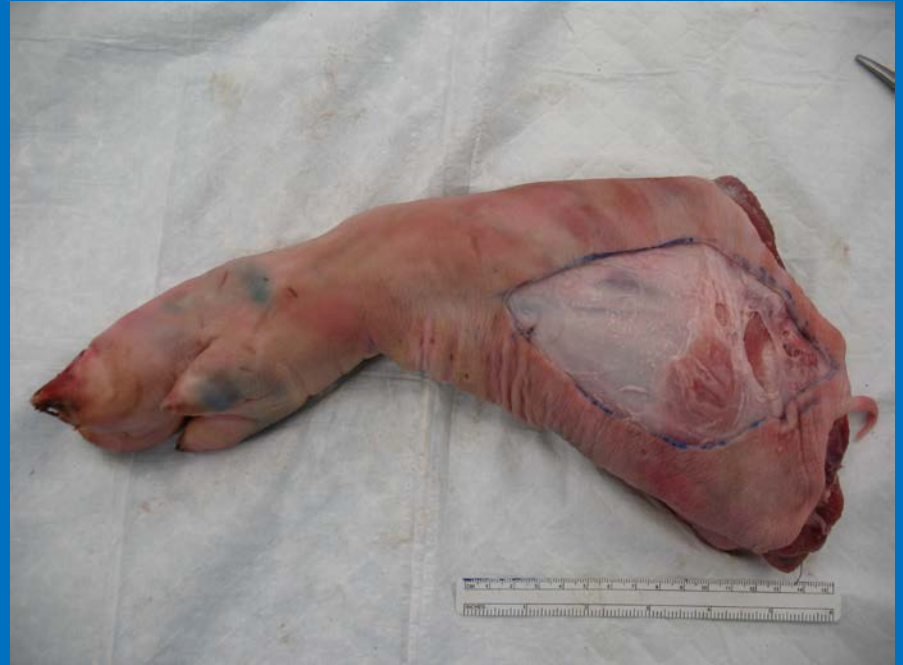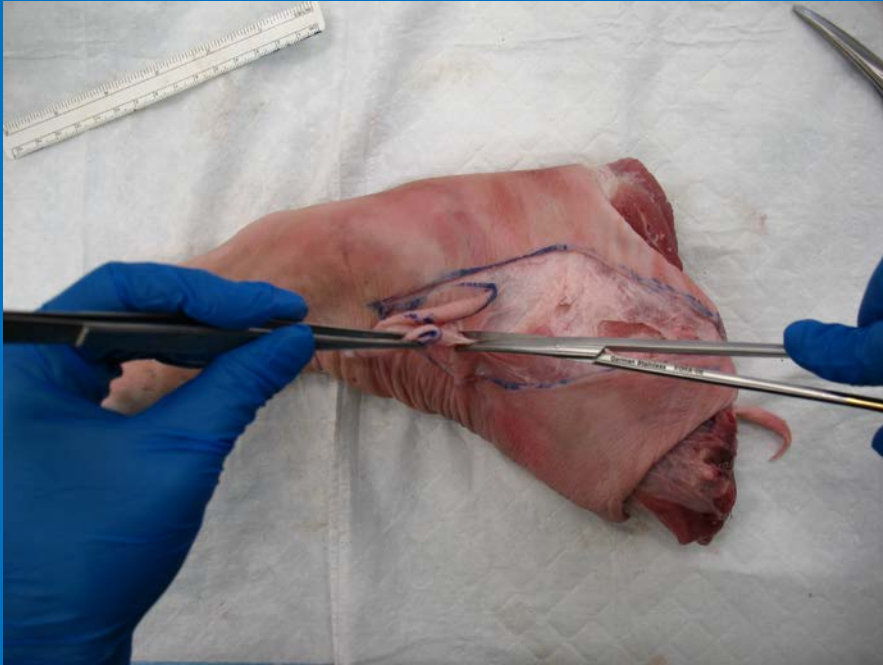
Plan a 2 cm margin around the melanoma

Procedure Step 2



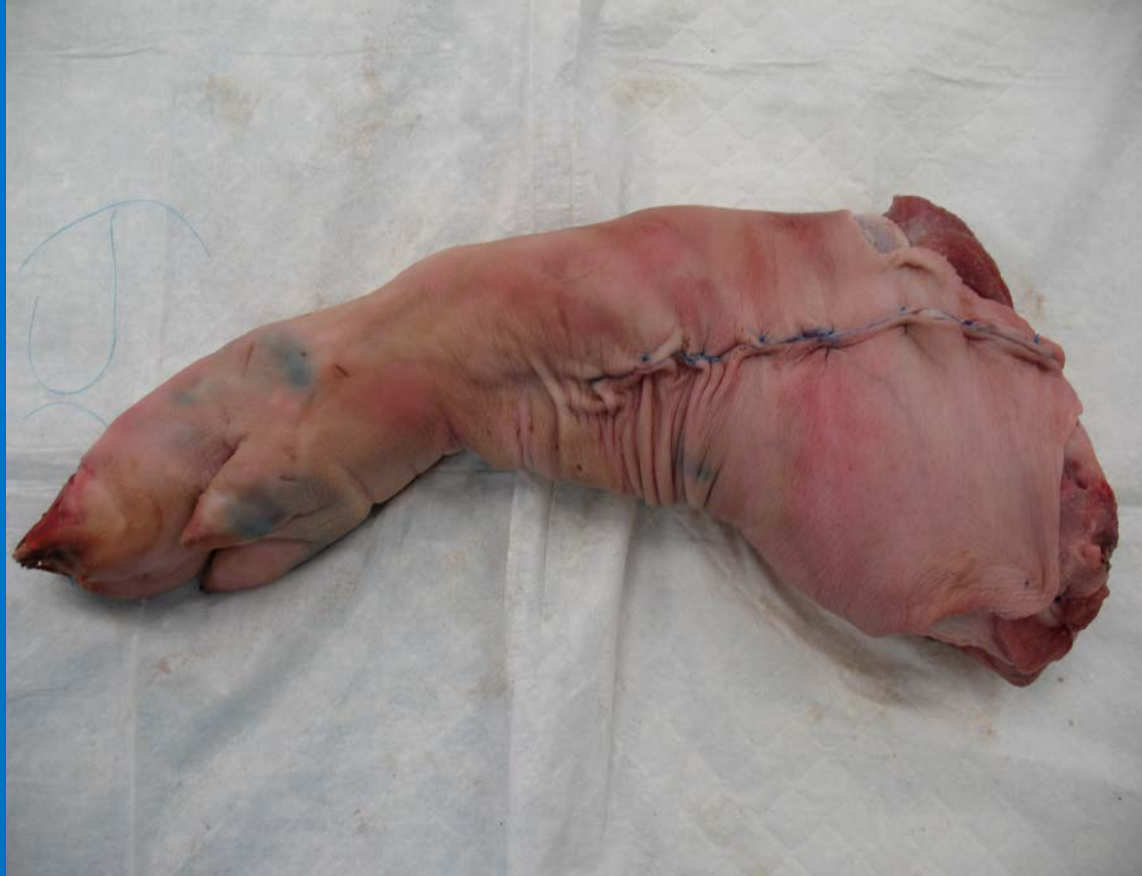Plan an elliptical incision with a length to width ratio of 3:1

Procedure Step 3



Use a scalpel to start and Metzbaum scissors to complete the melanoma excision from the underlying soft tissue

Procedure Step 4



Reapproximate skin with vertical mattress 3-0 nylon sutures

Checklist

- Provide tension to make straight sharp incision without skiving
- Appropriate margins obtained
- Full thickness excision performed
- Use appropriate tension and countertension to dissect the skin lesion out with electrocautery
- Secure closure and approximation of skin edges